

# Protective effect of *Artemisia herba-alba* extract on the liver of diabetic albino male rats

Nagwa Mohammed El-Sawi<sup>1</sup>, Ahmed Fathy Hassan<sup>1</sup>, Sahar Mohamed Gebriel<sup>2</sup>, Mohamed Ismael<sup>1</sup>, Mahmoud Hefny Gad<sup>3,\*</sup>

<sup>1</sup> Department of Chemistry, Faculty of Science, Sohag University, Sohag, 82524, Egypt.

<sup>2</sup> Histology Department, Faculty of Medicine, Sohag University, 82524, Egypt.

<sup>3</sup> Medicinal and Aromatic Plants Research Department, Horticulture Institute, Agricultural Research Center, Dokki, Giza, 12619, Egypt.

Received: 29 June 2022, Revised: 27 Jul., 2022, Accepted: 7 Aug. 2022.

Published online: 1 Sep. 2022

**Abstract:** Diabetes is a metabolic disorder that share a common underlying feature of hyperglycemia. In addition to hyperglycemia, diabetes is associated with microvascular and macrovascular complications that are the leading causes of morbidity and death in diabetics. *Artemisia herba-alba* (AHA) is an aromatic plant belongs to the *Artemisia* genus. The plant known in the traditional medicine for its preventive capacities against several chronic ailments. Forty-five albino adult male rats were randomly divided into 3 groups of 15 animals for each: group 1; control, group 2; STZ induced diabetes, group 3; protective. At the end of the experiment, rats were sacrificed, then we evaluated blood glucose level, serum insulin,  $\alpha$ -l-fucosidase (AFU), C-peptide, aspartate aminotransferase (AST), alanine aminotransferase (ALT), and total antioxidant capacity (TAC). Liver tissues were evaluated histologically by photomicrographs of liver sections from the three experimental groups using hematoxylin and eosin (H&E). The results of the AHA protective group showed minimal improvement with mild congestion, inflammatory cell infiltrations and some degenerated hepatocytes and the biochemical analysis confirm that. There is a slight improvement in TAC, ALT, AST, C-peptide, and insulin in protective group compared to diabetic group and significant improvement at AFU and  $\alpha$ -amylase in protective group compared to diabetic group.

**Keywords:** *Artemisia herba-alba*; liver; diabetes mellitus; protective effect; histology.

## 1 Introduction

One of the most common chronic diseases in the world is diabetes mellitus. In Egypt approximately 10% of Egyptians are type II diabetics in 2001 and this percentage will increase to 13.3 % by 2025 [1]. Diabetes is a metabolic disorder characterized by chronic hyperglycemia due to impaired regulation of carbohydrate metabolism due to impaired insulin secretion or impaired action of this hormone. Chronic hyperglycemia is associated with the development of serious long-term complications such as cardiovascular disease, chronic renal failure, and retinal damage [2]. Currently available anti-diabetes drugs include sulfonylureas, biguanides, thiazolidinediones, and  $\alpha$ -glucosidase inhibitors and are vastly used to control hyperglycemia. These drugs cannot significantly change the course of diabetic complications. They have limited use due to undesired pathological conditions and high secondary failure rates. Therefore, it is important to find a more effective anti-diabetes drug with fewer side effects.

Traditional medicinal plants with anti-diabetic properties can be a useful resource in the development of safe and effective oral anti-diabetic drugs [3]. Medicinal plants are essential resources for traditional medicine in treating pathological disorders, bacterial and fungal infections.

Regular consumption of some medicinal plants is associated with a low risk for developing chronic disease, suggesting prophylactic and protective effects against aging and organ failures. Most bioactive phytoconstituents mediate protective mechanisms by specific molecular pathways. However, the benefit of medicinal plants was determined empirically and little is known about their mechanisms of action [4]. Since ancient times, several cultures (including Arabic, North African, and European traditional medicine) have used the species *Artemisia* (family Asteraceae) extensively in folk medicine [5]. The medicinal plant *Artemisia herba-alba* (AHA) is well known for its ability to prevent chronic illnesses [4]. In Moroccan traditional medicine, it has been utilized to treat

\* Corresponding author E-mail: [mohamed2018521500879@gmail.com](mailto:mohamed2018521500879@gmail.com)

diabetes and/or arterial hypertension [6]. Based on practical observations and passed-down local knowledge, the *Artemisia herba-alba* plant is utilized in a variety of forms to treat several clinical disorders in people. A previous study provided more evidence for how the protective effect of AHA against chronic diseases or inflammation. Instead, the enhancement of glutathione metabolism by AHA extracts prepares the cells to respond to ROS and inflammatory circuits more quickly and effectively after severe infections or exposure to environmental pollutants [4]. This plant is one of the species that grows in Sinai. It's a little perennial dwarf shrub with greyish-white blooms. [7]. Oral hypoglycemic medications have made significant advances in the treatment of diabetes. As a result, various efforts have been made to find new effective and safe enzyme inhibitors from natural materials to manage diabetes [8], as well as to design physiologically useful foods to treat diabetes [9].

There is a recent study trying to detect the nephroprotective effect of *Artemisia herba-alba* aqueous extract in alloxan-induced diabetic rats [2] and prolonged protective effects of *Artemisia herba-alba* extracts [4]. The main goal of the present study is to evaluate the protective effect of *Artemisia herba-alba* extract on the liver in STZ-induced diabetic male rats.

## 2 Material and Methods

### Chemicals and apparatus

Streptozotocin (STZ) and dimethyl sulfoxide (DMSO) were procured from Biovision and Sigma-Aldrich, St. Louis, Missouri, USA. The MG was paid for the  $\alpha$ -amylase (Giza, Egypt). Bionime blood glucose analyzer (Switzerland). While insulin, C-peptide, and  $\alpha$ -L-fucosidase (AFU) tests were carried out using automated ELISA from Tecan (Männedorf, Switzerland), antioxidant assays were measured by spectrophotometer using kit from UviLine 9400 (Mainz, Germany). While  $\alpha$ -L-fucosidase (AFU) and C-peptide were acquired from Sunred, kit for serum insulin level was purchased from Sunlong (Shanghai, China) (Shanghai, China). Spectrum Diagnostics sells alanine aminotransferase (ALT) and aspartate aminotransferase (AST) (Qalyubia, Egypt). A colorimetric kit from Bio Diagnostics was used to measure the serum's total antioxidant capacity (TAC) (Giza, Egypt).

### Plant material and sample preparation

In June 2017, Prof. Dr. Ibrahim Elgarf (Cairo University, Egypt) collected *Artemisia herba-alba* Asso from Saint Catherine (South Sinai), Egypt. Extraction and sample preparation were prepared as mentioned in [10].

### Animals grouping and experimental design

Forty-five adult albino male rats were purchased from Animal House, (Faculty of Science, Sohag University, Sohag, Egypt). The body weight of them was  $(201 \pm 10 \text{ g})$ . before performing the experiments, the animals were adapted for 1 week were performed. All animals were kept

in 3 cages, 15 per group, in an environment with regulated lighting (12-hour cycle, lights on at 8:00 a.m.), temperature  $(25 \pm 1 \text{ }^\circ\text{C})$ , The animals were separated into three groups of 15 each, according to a random process. group (1) was kept as normal control and administered with saline (0.9%). However, group (2) was served as diabetic. Finally, group (3) was served as protective group were given AHA (50 mg/kg body weight) and later injected intraperitoneally with a single dose of STZ (50 mg/kg body weight). This work was performed according to the animal guidelines of Sohag University and approved by the ethical committee approval number (Sohag 22202102)

### Induction of diabetes

A single intraperitoneal (IP) injection of STZ (fresh solution) in citrate buffer (0.1 M, pH 4.5) at a dosage of 50 mg/kg body weight was used to cause diabetes in our research subject [11]. After 72 hrs of STZ administration, the blood glucose (FBG) levels were measured, where rats with  $\text{FBG} > 200 \text{ mg/dl}$  were considered diabetic and used in the experiment.

### Body weight (BW) and fasting blood glucose (FBG) measurements

At 0, 7 and 15 days, the level of FBG of each animal in the 3 groups was evaluated by using a Bionime blood glucose analyzer from the vein at the end of each rat's tail. Body weights at the beginning and finish, as well as % changes in FBG level, were noted.

### Collection of blood for biochemical parameters and liver tissue sampling

After 15 days, all rats in each group were sacrificed and blood samples were taken from the heart into plain tubes for biochemical testing. Before being used for various biochemical parameter analyses, serum was separated by centrifugation at 3000 g for 10 minutes, transferred into Eppendorf tubes, and frozen at  $-20 \text{ }^\circ\text{C}$ . Liver tissue samples were dissected and fixed in 10 neutral buffered formalin for 48 hours then processed into paraffin embedded blocks.

### Assessment of biochemical parameters (Biochemical analysis)

AFU, TAC, ALT, AST, C-peptide,  $\alpha$ -amylase, and insulin were measured in the serum using suitable kits. All assays were performed in accordance with the manufacturers' instructions and protocols. The serum  $\alpha$ -amylase was measured according to the method described in [12]. The serum insulin, C-peptide and AFU were assayed using ELISA kits. The serum insulin was performed according to the protocol in [13], while C-peptide was measured by described method in [14]. AFU was determined according to manufacturer protocol. The total antioxidant capacity of serum was assayed colorimetrically according to the described method in [15]. The serum ALT and AST were measured colorimetrically according to [16].

### Microscopic evaluation of liver tissue

Four um thickness tissue paraffin slices were cut on glass slides. The slides were deparaffinized in xylene, rehydrated with down grading concentrations of alcohol (100%, 90%, 80%, and 70%), and then placed in distilled water for five minutes. Hematoxylin and eosin (H&E) staining was done as described in [17].

### Statistical analysis

All results. were expressed as mean values with standard deviation ( $M \pm SD$ ). Means differences were analyzed using one-way analysis of variance (ANOVA), followed by the Newman-Keuls test. GraphPad Prism® Software version 5.00 (San Diego, CA) was used, and  $p$  values  $< 0.05$  were considered statistically significant.

## 3 Results and Discussion

Diabetes is a metabolic disorder that share a common underlying feature of hyperglycemia. In addition to hyperglycemia, diabetes is associated with microvascular and macrovascular complications that are the leading causes of morbidity and death in diabetics [3]. In Iraqi and Moroccan folk medicine *Artemisia herba-alba* plants have been used to treat a variety of diseases, including diabetes mellitus [6, 18]. In this study, some biochemical parameters, such as FBG,  $\alpha$ -amylase, insulin, and C-peptide, were examined to assess the protective effect of oral administration of AHA extract. Weight loss has long been recognized as one of the diabetes mellitus symptoms [19]. As shown in Table 1, the results showed highly significant reduction ( $***p < 0.05$ ) in the final body weight of diabetic group (2) with % of change (-15.79%), while significantly increase ( $**p < 0.01$ ) in the final body weight of the protected group (3) with % of change (14.87%).

The present results showed that the body weight of the protective group loss is lower than in the group (1). This may be due to the animals were stayed for two weeks before injection with STZ and the dissection occur after the injection by 3 days. Thus, there is no longer time to make significant change in the body weight loss % of change, or it may be due to the hypoglycemic effect of *Artemisia herba-alba* plant [20]. However, the body weight loss % of change of the diabetic group was clear, and this may be return to diabetes-related body weight reduction, which can be attributable to increase tissue protein loss and muscle wasting [21]. On the other hand, insulin insufficiency in diabetic rats led to a reduction in amino acids at the level of protein synthesis [21, 22]. Adipose tissue lipolysis and protein breakdown are brought on by insulin deficiency [23]. Biochemical analysis revealed that the intraperitoneal injection of STZ effectively caused diabetes in the normal rats. The protective group was fed for 15 days with AHA extract (50 mg/kg BW) as a protective dose before injected with STZ. As shown in Table 2, the result showed that the blood glucose level of the protective group was 310 mg/dl,

while diabetic group was 464 mg/dl. Although the protective dose reduces FBG with 49%, however rats still diabetic (FBG  $> 200$ ). Therefore, the protective effect may be due to the hypoglycemic effect of the *Artemisia herba-alba* plant [20].

**Table 1:** Effect of *Artemisia herba-alba* extract on the body weight. (Values are provided as Mean  $\pm$  SD for each group, with  $n=15$  in each)

Group	Body weight (kg)		
	Initial	Final	Percent of Change (%)
G.1	0.200 $\pm$ 28.61	0.239 $\pm$ 9.99	19.45
G.2	0.205 $\pm$ 6.63	0.173 $\pm$ 4.90**	-15.79
G.3	0.195 $\pm$ 3.12	0.224 $\pm$ 17.40*	14.87

Significant change in comparison between group 1 and other groups, where \* $p < 0.05$ ; and \*\* $p < 0.01$ . The statistical analysis was performed using One-way ANOVA, followed by the Newman-Keuls test.

**Table 2:** Effect of *Artemisia herba-alba* extract on the fast blood glucose (FBG). (Values are provided as Mean  $\pm$  SD for each group, with  $n=15$  in each)

Group	Fast blood glucose level (mg/dl)			
	Day (0)	Day (7)	Final	Percent of Change (%)
G.1	96.75 $\pm$ 11.73	94.65 $\pm$ 8.47	97.00 $\pm$ 4.55	2.30
G. 2	464 $\pm$ 27.23***	430.50 $\pm$ 18.89***	450.99 $\pm$ 29.40***	24.40
G. 3	103 $\pm$ 16.80***	95 $\pm$ 6.80***	310 $\pm$ 22.70***	200.10

Significant change in comparison between group 1 and other groups, where \*\*\* $p < 0.001$ . The statistical analysis was performed using One-way ANOVA followed by the Newman-Keuls test.

C-peptide,  $\alpha$ -amylase and insulin in Table 3 showed that  $\alpha$ -amylase is highly significant increased ( $p < 0.001$ ) in the diabetic and protective group compared to control group and the protective group has significant decrease ( $**p < 0.01$ ) with the diabetic group, this is may be because  $\alpha$ -amylase increase as a result of diabetes mellitus and group [24]. But the value of the protective group is less than the value of the diabetic group and this is because of the potent  $\alpha$ -amylase inhibitory activity of aqueous extract of AHA [25]. The insulin level of group (1) decreases significantly at  $p < 0.05$  with the diabetic group and protective group. Due to STZ's rapid-cell depletion, which caused hyperglycemia and lowered insulin release, the insulin level in diabetic group decreased. The release of inadequate amounts of insulin causes hyperglycemia, which causes diabetes complications and oxidative damage due to production of reactive oxygen species [26]. The insulin level of the protective group was found to be increased compared to the diabetic group, which means that AHA has protective effect and slightly improve the insulin level.

The results of ALT, AST AFU and TAC were shown

in Table 4. ALT and AST of the control group are high significantly increase ( $p < 0.001$ ) compared to the protective and diabetic groups. In the present study, the ALT and AST activities were increased in serum significantly in the diabetic group and protective group due to the damage to liver compared to the control group and this elevation in activities of AST and ALT serum in a diabetic is agreed with [27]. TAC in the control group was found to be high significantly at  $p < 0.001$  compared to the diabetic group and protective. AHA has a high antioxidant capacity so it has a high-potency nutraceutical with antioxidant properties [28]. There is a slight improvement in TAC mean value of the protective group compared to the diabetic group, which may be due to the presence of phenolic and flavonoid substances in AHA, which is considered a source of natural antioxidants and  $\alpha$ -amylase inhibitor [25].

The control group AFU mean value is significant decrease compared to the diabetic group ( $*p < 0.05$ ) and non-significant compared to the protective group. Protective group is significant compared to the diabetic group ( $**p < 0.01$ ). AFU is a member of the group of lysosome acidic hydrolases [29]. Elevated blood AFU levels have been associated with liver disorders like cirrhosis, hepatitis, hepatic malignancy, and hepatotoxicity [15]. In the present study, the increase in AFU activity may be due to diabetes mellitus as AFU increase significantly in the diabetics unlike controls [30] and improvement in protective group may be a result of the hypoglycemic effect of AHA extract [31].

**Table 3:** Effect of *Artemisia herba-alba* extract on the serum of  $\alpha$ -amylase, C-peptide and insulin. (Data are reported as Mean  $\pm$  SD ( $n=15$ ))

Parameter	Control	Diabetic	Protective
$\alpha$ -amylase (U/L)	37.86 $\pm$ 4.97	131.70 $\pm$ 8.03***	102.6 $\pm$ 5.81***,##
C-peptide (pmol/mL)	0.94 $\pm$ 0.03	0.62 $\pm$ 0.04***	0.71 $\pm$ 0.02**,#ns
Insulin (mU/L)	1.88 $\pm$ 0.13	0.69 $\pm$ 0.05**	1.163 $\pm$ 0.22***,#ns

Significant change in comparison between group 1 and other groups, where  $**p < 0.01$ ;  $***p < 0.001$ . Significant change in comparison between group 2 and 3,  $###p < 0.001$  and  $^{\#n.s}$  non-significant ( $p > 0.05$ ). The significance was performed using One-way ANOVA, followed by the Newman-Keuls test.

**Table 4:** Biochemical liver investigations of *Artemisia herba-alba* extract on ALT, AST, TAC and AFU. (Data are reported as Mean  $\pm$  SD ( $n=15$ )).

Parameter	Control	Diabetic	Protective
ALT (U/ml)	20.00 $\pm$ 2.36	75.30 $\pm$ 4.11***	73.4 $\pm$ 3.55***,#ns
AST (U/ml)	28.70 $\pm$ 2.12	75.30 $\pm$ 3.69***	69.00 $\pm$ 3.55***,#ns
TAC (mmol/l)	1.25 $\pm$ 0.68	0.27 $\pm$ 0.05***	0.56 $\pm$ 0.17**,#ns
AFU (ng/ml)	0.39 $\pm$ 0.10	0.62 $\pm$ 0.03*	0.30 $\pm$ 0.05 <sup>ns</sup> ,##

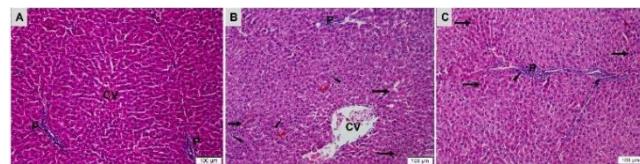
Significant change in comparison between group 1 and other

groups, where  $*p < 0.05$ ;  $***p < 0.001$ ; and n.s non-significant ( $p > 0.05$ ). Significant change in comparison between group 2 and 3,  $##p < 0.01$ ; and  $^{\#n.s}$  non-significant ( $p > 0.05$ ). The statistical analysis was performed using One-way ANOVA, followed by the Newman-Keuls test.

### Histopathological examination

Liver tissue sections from all experimental groups stained by H&E. The control liver parenchyma was composed of classical hepatic lobules with an approximately hexagonal outline that were distinguished by the presence of the central vein in the center and peripheral portal triads. Hepatocyte plates with a blood sinusoid in between, oriented radially from the central vein to the periphery. In the blood sinusoids, portal vessels, and central veins of diabetic groups (B), there was noticeably more congested and dilated. Apoptotic hepatocytes displayed more acidophilic cytoplasm with a tiny, darkly stained nucleus. Infiltration of inflammatory cells was also clearly visible. AHA protective group (C) showed very little improvement, with mild congestion in the blood sinusoids inflammatory cellular infiltration, and some hepatocytes appeared with more acidophilic cytoplasm, and dense nuclei (apoptosis) (Fig. 1). This histological figure of hepatotoxicity induced by diabetes [32].

STZ has a diabetogenic effect as it has selective destructive action on pancreatic Beta cells inducing insulin insufficiency, hyperglycaemia as a characteristic picture of diabetes mellitus type 1 DM1 [33]. The liver is greatly affected by DM1 as it is insulin dependent tissue and play an important role in glucose and lipid metabolism (glycogenogenesis and glycogenolysis [34].



**Fig. 1.** Photomicrographs of liver tissue sections from all experimental groups (H&E). (A) control group; show normal liver tissue, histological structure of central vein (CV), portal area (P) and hepatocytes, (B) diabetic group; show loss of normal liver tissue structure, show massively dilated central vein (CV) and inflammatory cellular infiltration (arrow heads) some hepatocytes show small dense apoptotic nuclei with more acidophilic cytoplasm (black arrow). In addition, other cells show vacuolated cytoplasm (red arrow). while (C) protective group; show very mild improvement with inflammatory cellular infiltration at portal area (P) (arrow head), and many hepatocytes with small dense nuclei and more acidophilic cytoplasm (black arrow) apoptotic liver cells.

## 4 Conclusion

The present study found that AHA extract slightly improve TAC, ALT, AST, C-peptide, and insulin in diabetic rats. However, a significant improved was noticed in AFU and  $\alpha$ -amylase, which indicated the protective efficacy of the extract in against diabetes may be due its content of antioxidant compounds.

## 5 References

1. Kasim, K., et al., Peripheral neuropathy in type-II diabetic patients attending diabetic clinics in Al-Azhar University Hospitals, Egypt. *International Journal of Diabetes Mellitus*, 2010. 2(1): p. 20-23.
2. Sekiou, O., et al., Nephroprotective effect of *Artemisia herba alba* aqueous extract in alloxan-induced diabetic rats. *Journal of Traditional and Complementary Medicine*, 2021. 11(1): p. 53-61.
3. Surya, S., et al., Diabetes mellitus and medicinal plants-a review. *Asian Pacific Journal of Tropical Disease*, 2014. 4(5): p. 337-347.
4. Bouchara, N., et al., Anti-inflammatory and prolonged protective effects of *Artemisia herba-alba* extracts via glutathione metabolism reinforcement. *South African Journal of Botany*, 2021. 142: p. 206-215.
5. Imane, B., Effect of phenolic extracts of Algeri growth and adherence of Staphylo pathogens responsib. 2017.
6. Ziyayat, A., et al., Phytotherapy of hypertension and diabetes in oriental Morocco. *Journal of ethnopharmacology*, 1997. 58(1): p. 45-54.
7. Mohamed, A.E.-H.H., et al., Chemical constituents and biological activities of *Artemisia herba-alba*. *Records of Natural Products*, 2010. 4(1).
8. Matsui, T., et al.,  $\alpha$ -Glucosidase inhibitory action of natural acylated anthocyanins. 1. Survey of natural pigments with potent inhibitory activity. *Journal of Agricultural and Food Chemistry*, 2001. 49(4): p. 1948-1951.
9. Wang, H., Y.-J. Du, and H.-C. Song,  $\alpha$ -Glucosidase and  $\alpha$ -amylase inhibitory activities of guava leaves. *Food chemistry*, 2010. 123(1): p. 6-13.
10. Mohamed, T.A., et al., New antimicrobial metabolites from the medicinal herb *Artemisia herba-Alba*. *Natural Product Research*, 2021. 35(12): p. 1959-1967.
11. Saha, P., et al., Antidiabetic and antioxidant activity of methanol extract of *Ipomoea reptans* Poir aerial parts in streptozotocin induced diabetic rats. *Pharmacologyonline*, 2008. 1: p. 409-421.
12. Determination of serum  $\alpha$ -amylase by kinetic method. [cited 2022 27 January]; Available from: <https://medlab.ly/DELMA%20PDF/amylase.pdf>.
13. Hussein, J., et al., Insulin resistance and oxidative stress in diabetic rats treated with flaxseed oil. *Journal of Medicinal Plants Research*, 2012. 6(42): p. 5499-5506.
14. El-Ashmawy, N.E., et al., Effect of human umbilical cord blood-derived mononuclear cells on diabetic nephropathy in rats. *Biomedicine & Pharmacotherapy*, 2018. 97: p. 1040-1045.
15. ElSawi, N.M., et al., Copper (I) Nicotinate complex Abrogates Acrylamide Induced Hepatotoxicity in Male Rats: *Biochemical and Histological Studies*. 2019.
16. Determination of ALT and AST by calorimetric method. 2022 27 January Available from: [http://www.spectrum-diagnostics.com/new/p\\_01\\_02\\_Enzymes.php](http://www.spectrum-diagnostics.com/new/p_01_02_Enzymes.php)
17. Suvarna, K.S., C. Layton, and J.D. Bancroft, *Bancroft's theory and practice of histological techniques E-Book*. 2018: Elsevier health sciences.
18. Twaij, H.A.A. and A.A. Al-Badr, Hypoglycemic activity of *Artemisia herba alba*. *Journal of ethnopharmacology*, 1988. 24(2-3): p. 123-126.
19. El-Sawi, N., et al., Evaluation of antidiabetic activity of *Ipomoea aquatica* fractions in streptozotocin induced diabetic in male rat model. *Sohag J of Science*, 2017. 2(1): p. 9-17.
20. Ahmad, Z.A.-k. and B.A. Abdul-Hussian, Effect of *Artemisia* herb on induced hyperglycemia in wistar rats. *Al-Qadisiyah Journal of Veterinary Medicine Sciences*, 2016. 15(2): p. 63-69.
21. Kato, A., et al., Protective effects of dietary chamomile tea on diabetic complications. *Journal of agricultural and food chemistry*, 2008. 56(17): p. 8206-8211.
22. Mohamed, N.A. and O.A. Nassier, The antihyperglycaemic effect of the aqueous extract of *Origanium vulgare* leaves in streptozotocin-induced diabetic rats. *Jordan Journal of Biological Sciences*, 2013. 6(1): p. 31-38.
23. Vasudevan, D.M. and S. Sreekumari, *Signs and symptoms of lead poisoning. Textbook of Biochemistry for Medical Students*. 5th ed. Jaypee Brothers, Medical publishers Ltd, New Delhi, 2007: p. 348-349.
24. Ademiluyi, A.O., et al., Effect of fermented soybean condiment supplemented diet on  $\alpha$ -amylase and  $\alpha$ -glucosidase activities in Streptozotocin-induced diabetic rats. *Journal of Functional Foods*, 2014. 9: p. 1-9.
25. Al-Kharabsheh, S., et al., Antioxidant activity and  $\alpha$ -amylase inhibitory effect of selected medicinal plants grown in Jordan: an in-vitro study. *Journal of The Arab Society for Medical Research*, 2017. 12(1): p. 19.
26. Ahmad, U. and R.S. Ahmad, Anti diabetic property of aqueous extract of *Stevia rebaudiana* Bertoni leaves in Streptozotocin-induced diabetes in albino rats. *BMC Complementary and Alternative Medicine*, 2018. 18(1): p. 179.
27. Ozkol, H., et al., Therapeutic potential of some plant extracts used in Turkish traditional medicine on streptozocin-induced

- 
- type 1 diabetes mellitus in rats. *The Journal of membrane biology*, 2013. 246(1): p. 47-55.
28. Bourgou, S., et al., LC-ESI-TOF-MS and GC-MS profiling of Artemisia herba-alba and evaluation of its bioactive properties. *Food Research International*, 2017. 99: p. 702-712.
29. Shuang, Z., et al., Alpha-L-fucosidase serves as a prognostic indicator for intrahepatic cholangiocarcinoma and inhibits its invasion capacity. *BioMed research international*, 2018. 2018.
30. Reglero, A., M.I. Carretero, and J. Cabezas, Increased serum  $\alpha$ -L-fucosidase and  $\beta$ -N-acetylglucosaminidase activities in diabetic, cirrhotic and gastric cancer patients. *Clinica Chimica Acta*, 1980. 103(2): p. 155-158.
31. Awad, N.E., et al., Hypoglycemic activity of Artemisia herba-alba (Asso) used in Egyptian traditional medicine as hypoglycemic remedy. *J. Appl. Pharm. Sci*, 2012. 2: p. 30-39.
32. Sasse, D., U.M. Spornitz, and I.P. Maly, Liver architecture. *Enzyme*, 1992. 46: p. 8-8.
33. Kolb, H., Mouse models of insulin-dependent diabetes - low-dose streptozocin-induced diabetes and nonobese diabetic (nod) mice. *Diabetes-Metabolism Reviews*, 1987. 3(3): p. 751-778.
34. Tappy, L. and K. Minehira, New data and new concepts on the role of the liver in glucose homeostasis. *Curr Opin Clin Nutr Metab Care*, 2001. 4(4): p. 273-7.